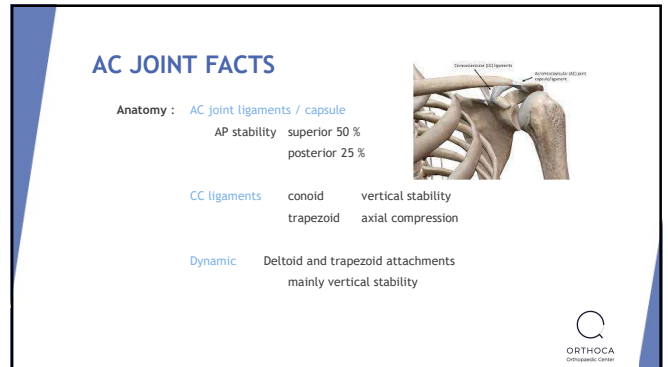
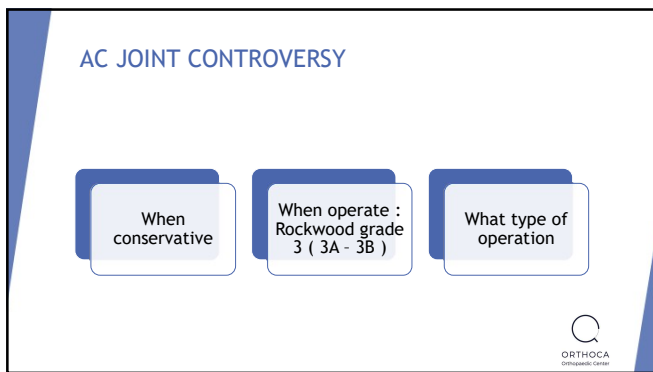


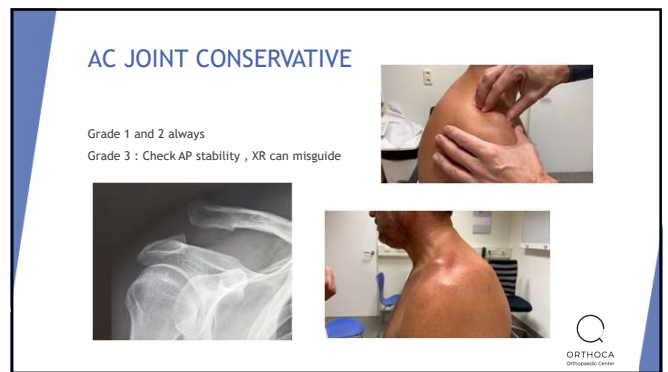1



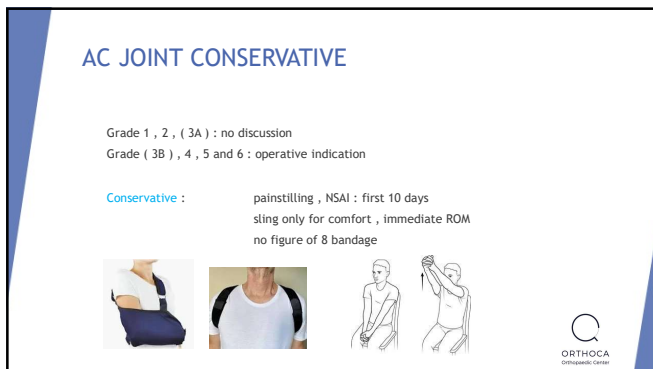
2



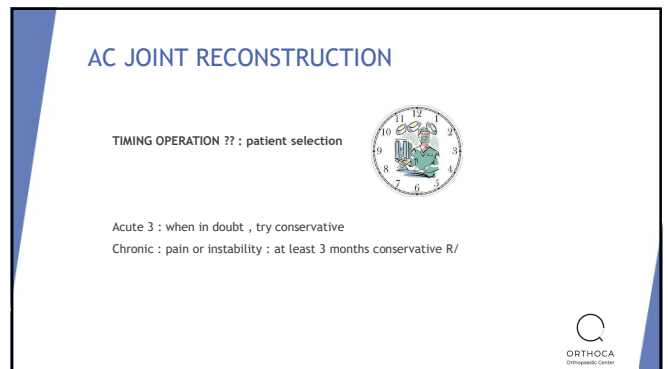
3



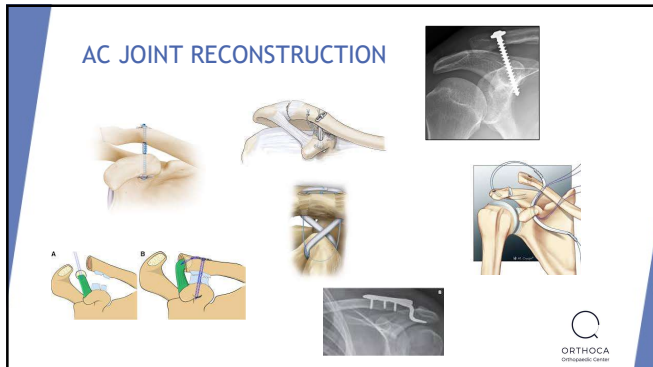
4



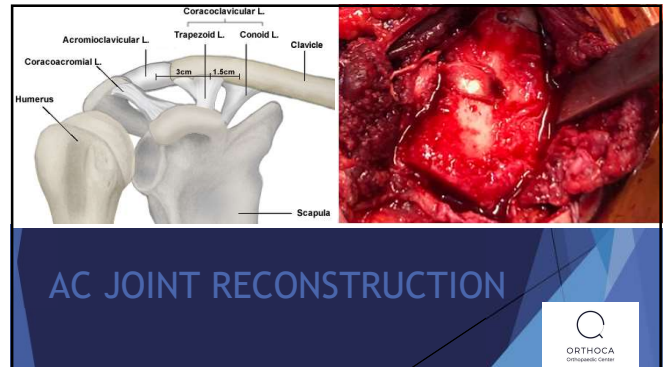
5



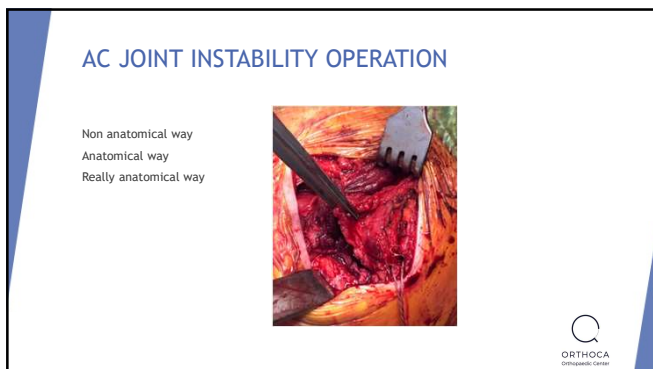
6



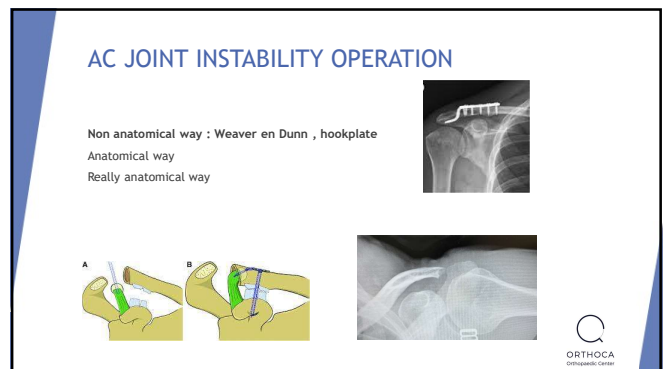7



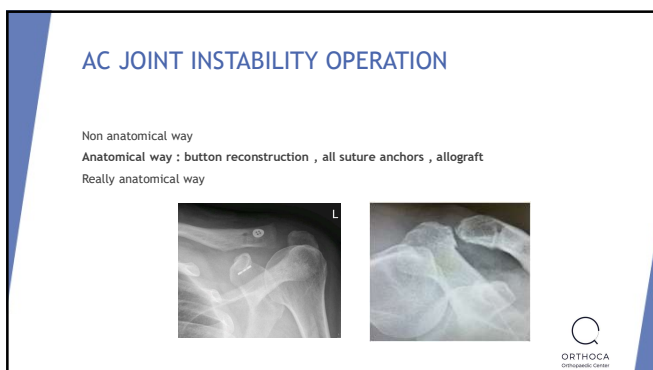
8



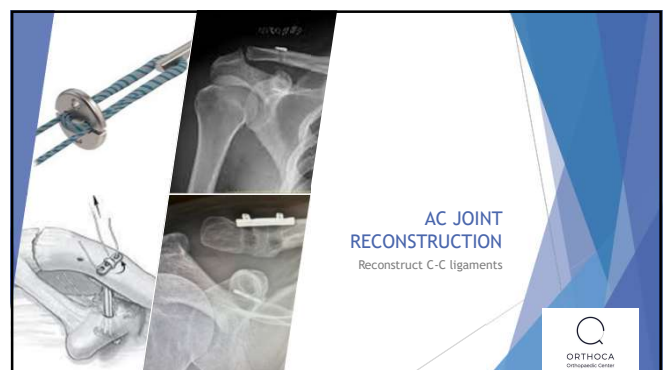9



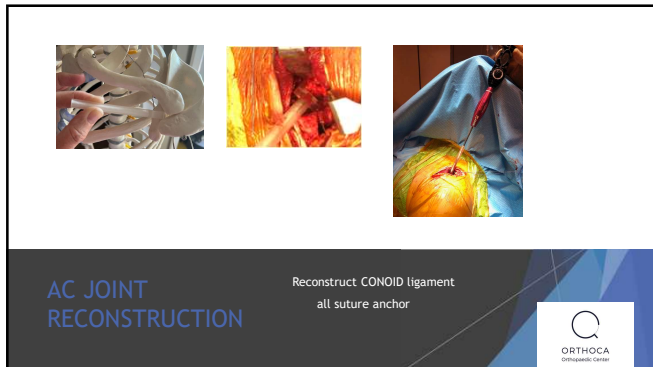10



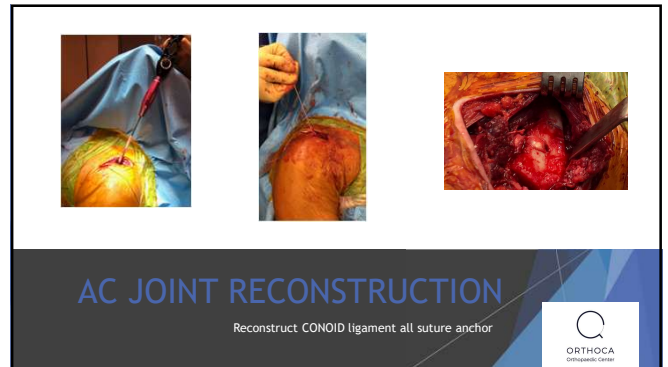
11



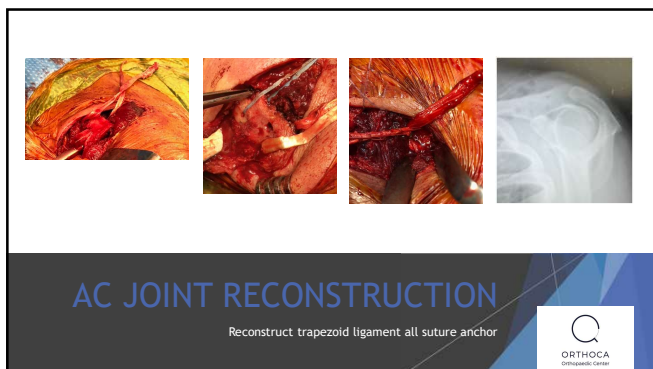
12



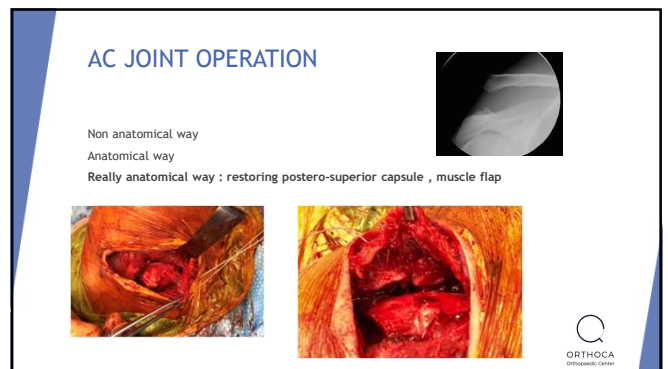
13



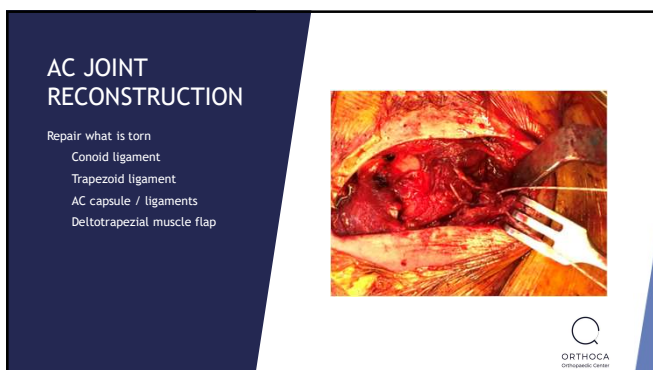
14



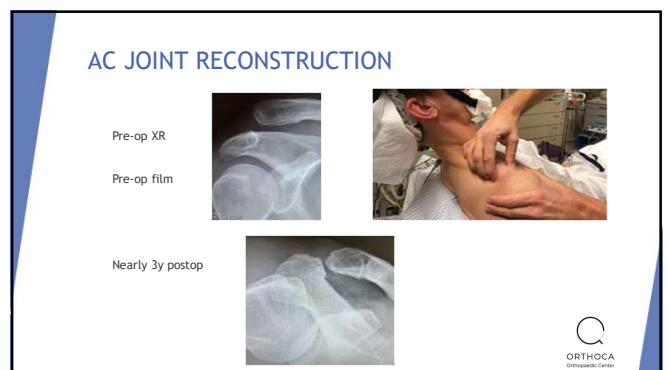
15



16



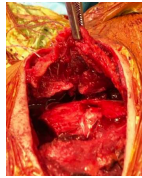
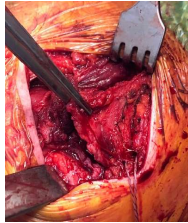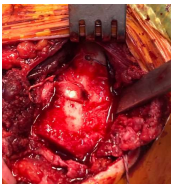17



18

AC JOINT RECONSTRUCTION

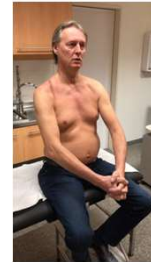Final result



19

AC JOINT RECONSTRUCTION

2w postop



20



Repair of ACJ instability

Single-centre comparison of three surgical techniques for ACJ instability

Vleugels Karolien ^(1,3)
Mertens Joren ^(1,3)
Jansen Nick ⁽¹⁾
Declercq Geert ⁽¹⁾
Verborgt Olivier ^(1,2,3,4)

1 Orthopaedic Center Antwerp (Orthoca), AZ Monica, Antwerp, Belgium
2 University Hospital of Antwerp, Antwerp, Belgium
3 Faculty of Medicine and Health Sciences, University of Antwerp, Antwerp, Belgium
4 Research Group MOVANT, Department of Rehabilitation Sciences and Physiotherapy (BREVAN), University of Antwerp, Antwerp, Belgium

21

CONCLUSION

No significant difference in **PROM's** and **LOR** for ACJ stabilisation for all three techniques

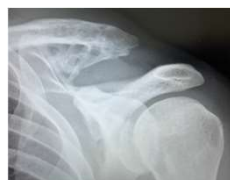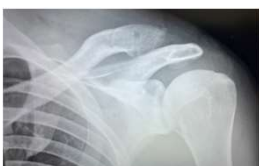LOR occurred in 7.5% of our patients, which is low compared to other studies

LOR does not correlate with worse clinical outcome scores.

22

COMPLICATIONS Triple A Recon

1 day post op



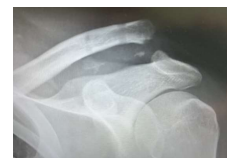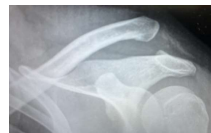1 year postop



23

FAILED TRIPLE A RECONSTRUCTION

RW 3B recon : Failed on XR ...

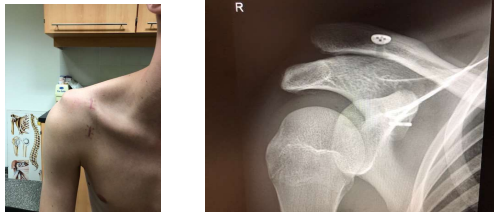


... but able to do everything



24

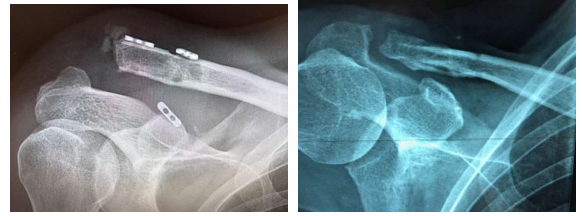
Failed AC reconstruction



ORTHOCA
Orthopaedic Center

25

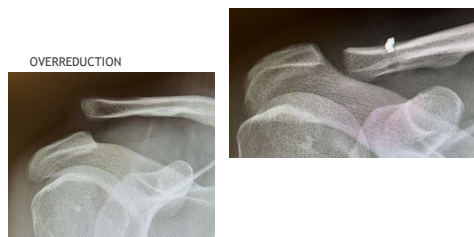
Failed AC reconstruction



ORTHOCA
Orthopaedic Center

26

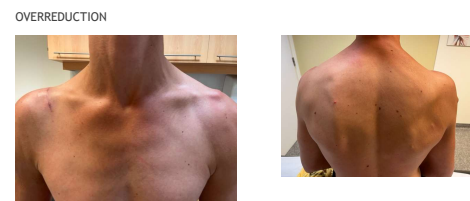Failed AC RECONSTRUCTION



ORTHOCA
Orthopaedic Center

27

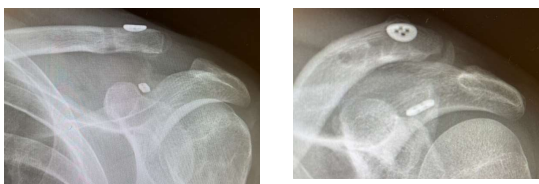FAILED AC RECONSTRUCTION



ORTHOCA
Orthopaedic Center

28

Failed AC RECONSTRUCTION



ORTHOCA
Orthopaedic Center

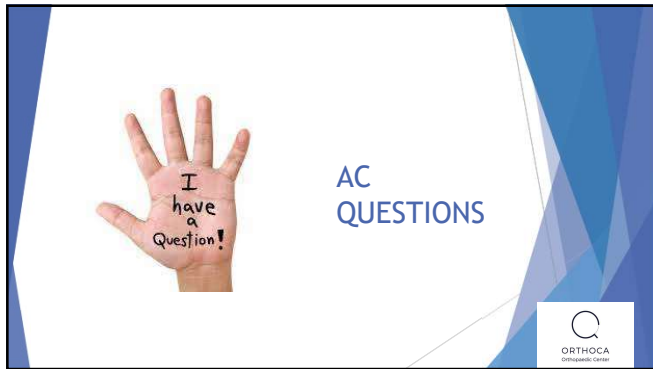
29

AC LESSONS LEARNED


Understand the **anatomy** of the **AC joint** and understand the pathology of the lesion
When conservative, and how we manage that
When **operate**: selection patient
go for **anatomic repair**
when you use metalwork: KNOW your system !!
"rather a little higher than a little tighter"
drill your patient in postop rehab: 2w sling and 6 weeks no active 90°+

ORTHOCA
Orthopaedic Center


30



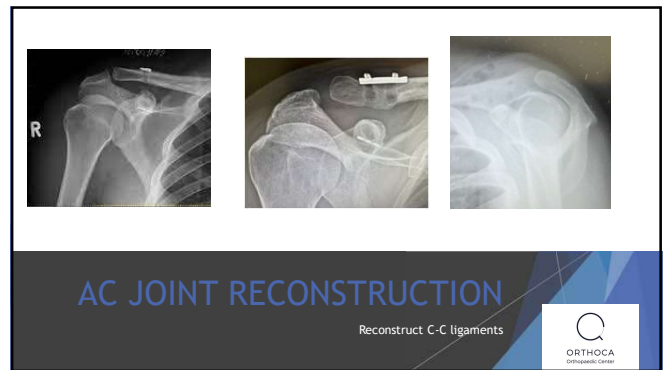
31




32



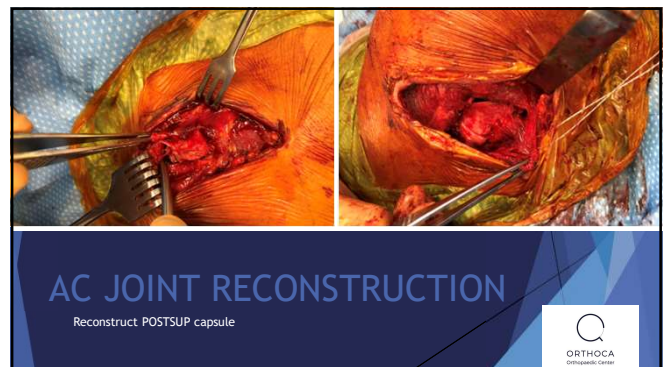
33



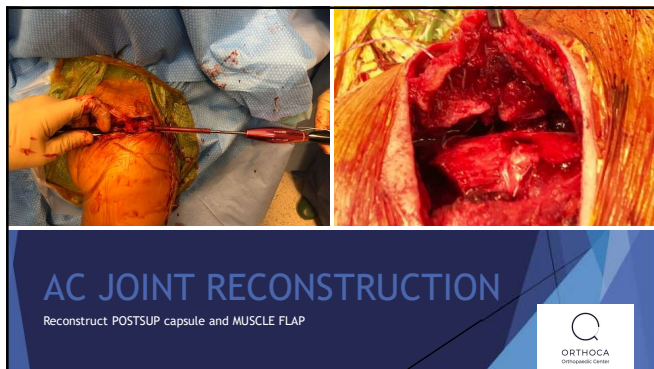
34



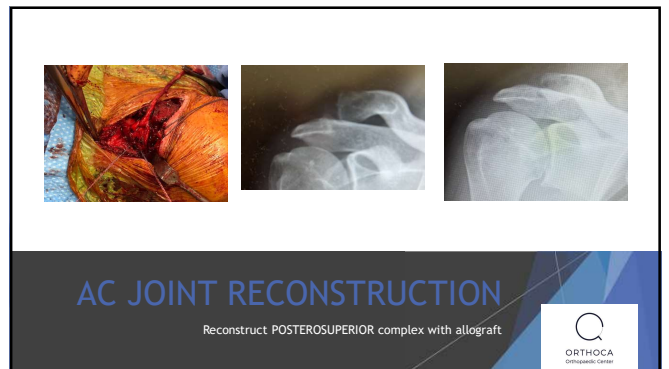
35



36



37



38